Osteology

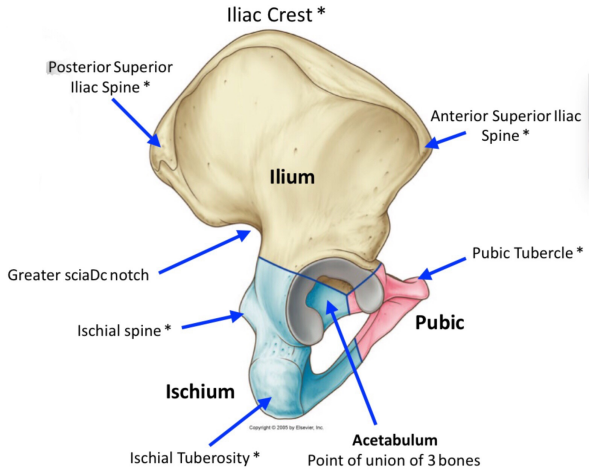

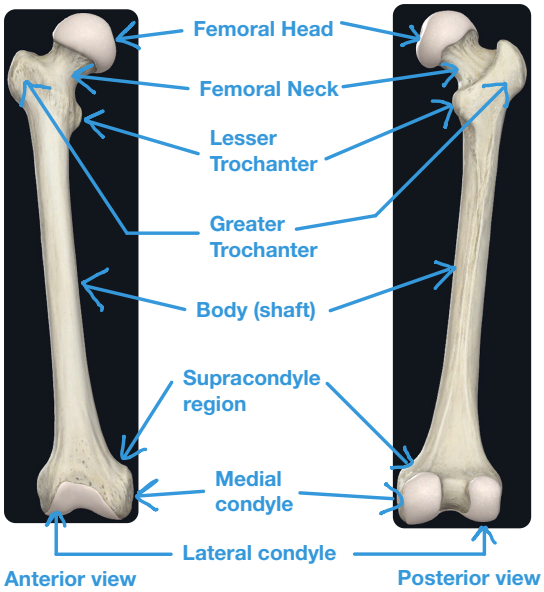

Ligaments

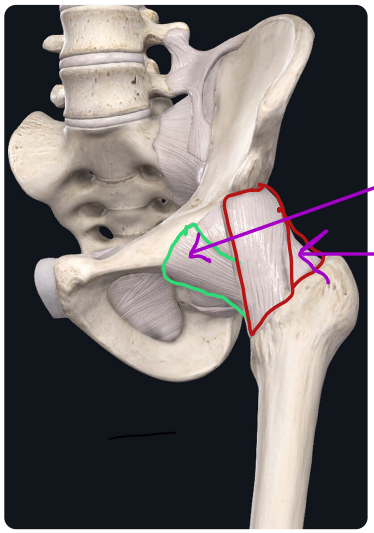

Anterior view

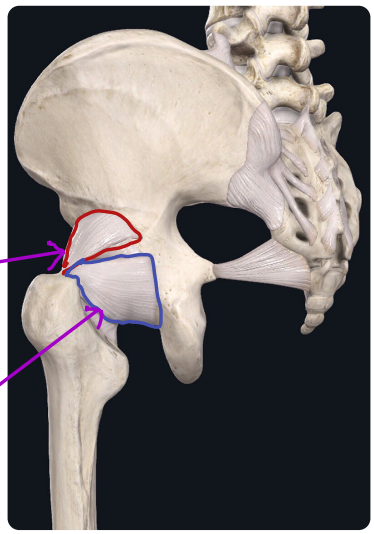

Posterior view

Functions of the Hip

- Connection between Axial and appendicular skeleton
- Distributes weight to lower limbs
- Allows locomotion + standing

Acetabular labrum

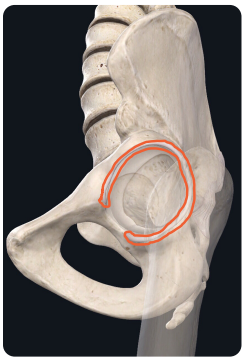

- Fibrocartilage rim
- It deepens the acetabulum
  - Increases stability

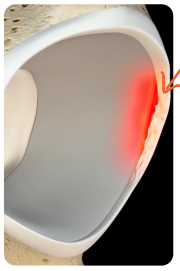

Hip Bursae

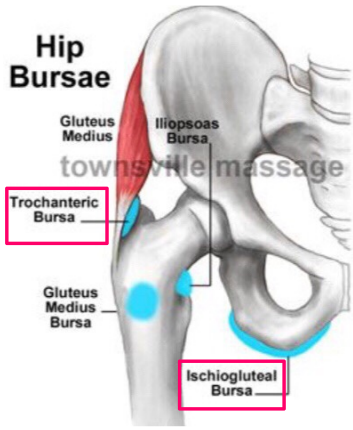

- The trochanteric and ischioguteal bursae are the important bursae mentioned

Muscles

Lateral rotators

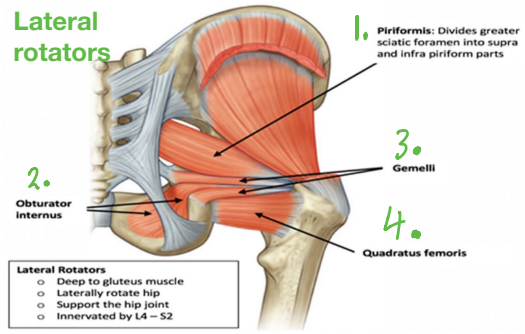

- **Pigs**
  - Piriformis
- **Often**
  - Obturator internus
- **Growl**
  - Superior/inferior Gemelli
- **Quietly**
  - Quadratus femoris

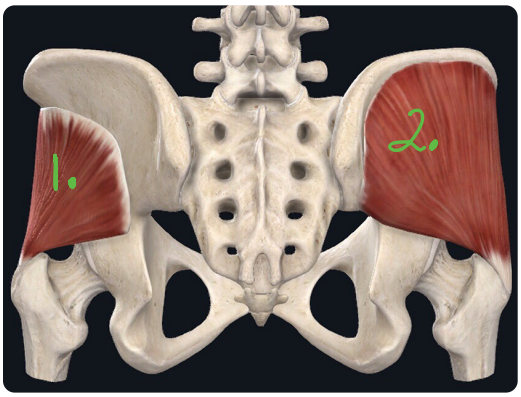

- 1=Gluteus minimus
- 2=Gluteus medius
- Both supplied by superior Gluteal Nerve

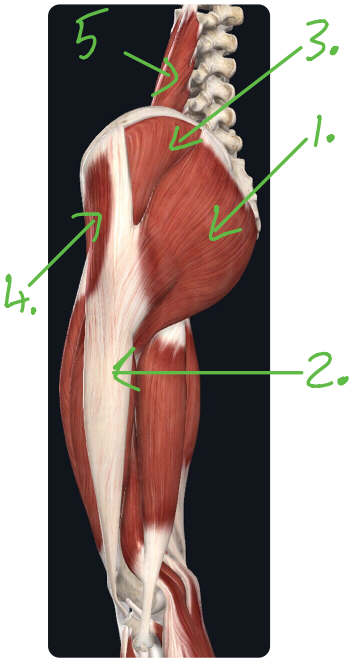

- 1=Gluteus Maximus
  - Inferior Gluteal nerve
- 2=illiotibial tract
- 3=Gluteus medius
- 4=tenser fascia latae
  - Superior Gluteal nerve
- 5=Psoas Major + Minor

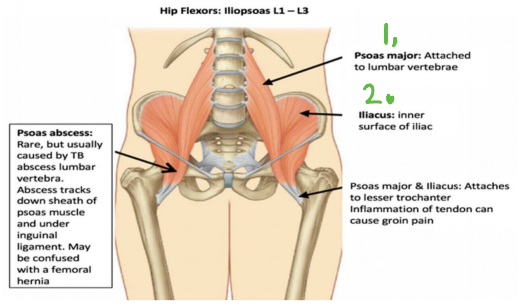

1+2=illiopsoas

- 1=Psoas major
- 2=illiacus
- Innervated by spinal nerve L1-3
- Attach onto Lesser trochanter
  - Avulsion fracture cause by hyper extension

Medial rotators

- **Illiopsoas**
- **Gluteus medius +minimus**

Nerves

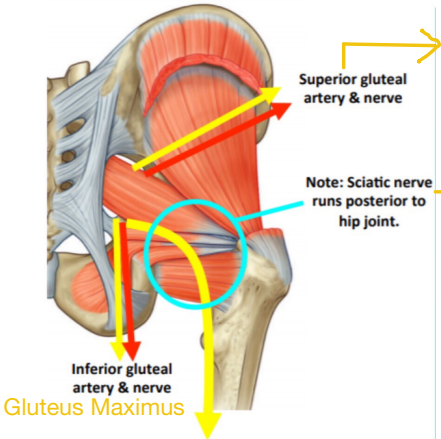

Gluteus medius + minimus + tenser fascia

Posterior dislocation of hip->sciatic nerve damage

Sciatic nerve (L4-S3)
Passes distally in posterior thigh compartment and supplies posterior compartment of thigh and the leg & foot

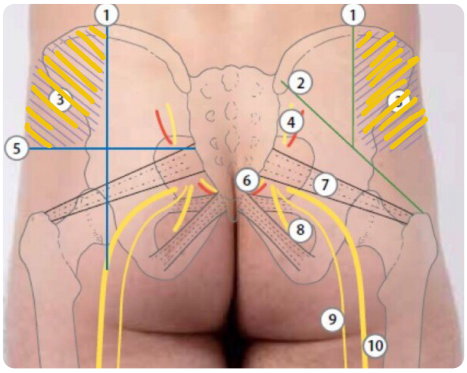

- Hip injections must be done in UPPER QUADRANT
- Reduces risk of sciatic nerve damage

Arteries of Gluteal region

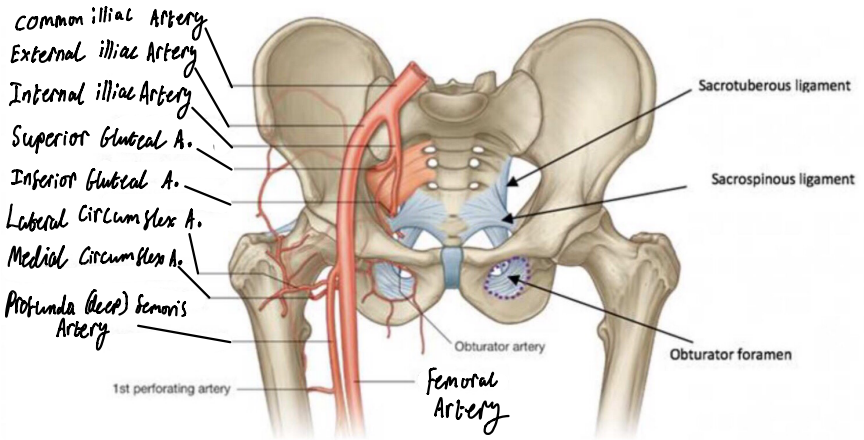

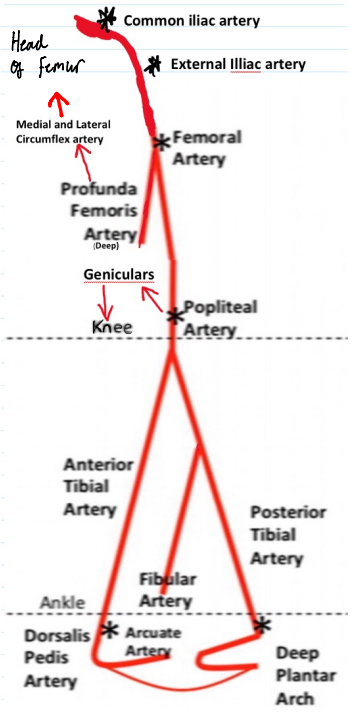

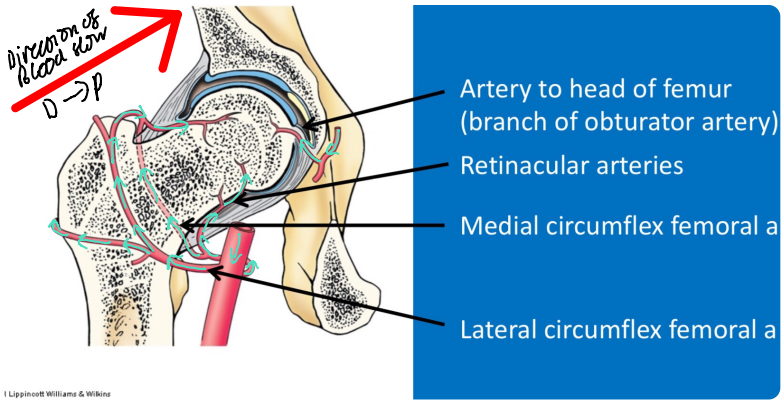

- Blood flows Distal ->Proximal in the femoral head
  - Intracapsular fracture ->circumflex artery damage
  - Leads to avascular necrosis of femoral head
    - Branch of obturator artery can not compensate
  - Requires hip replacement
- Extracapsular fracture = No risk of avascular necrosis

Veins

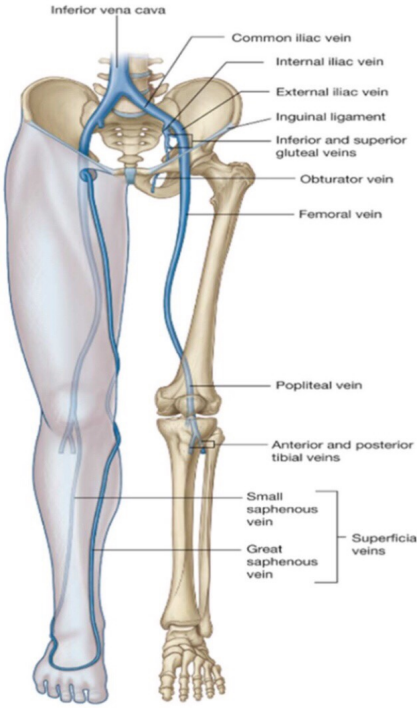

- Drainage occurs superficial-> deep via perforating veins
- Valves prevent backflow
- Muscles assist venous return via muscle pump
- Veins wide diameter reduces pressure + resistance

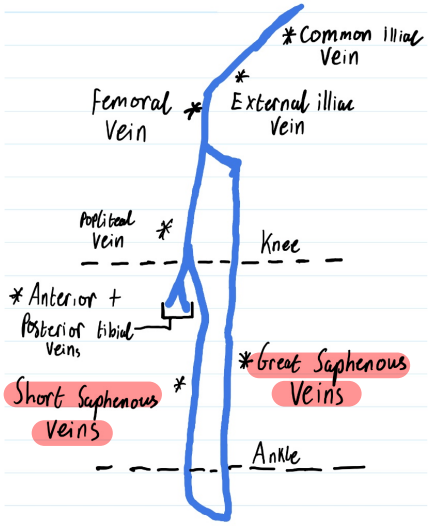

Venous conditions
- Deep veins Thrombosis
  - Risk of Pulmonary embolism
  - Caused due to valvular damage/incompetency
- Varicose veins
- Postphlebitic syndrome

*highlighted= superficial Veins

Varicose veins

DVT

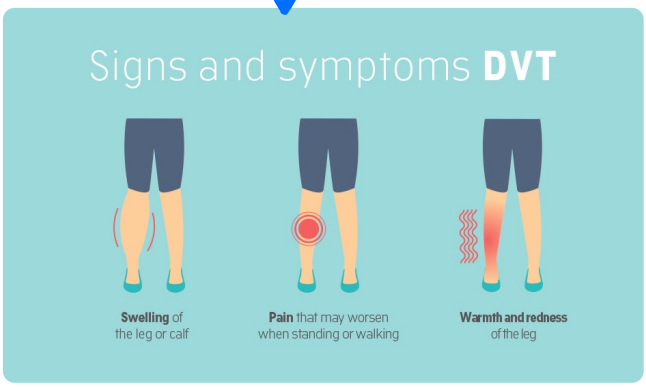

Femoral Triangle

NAVL

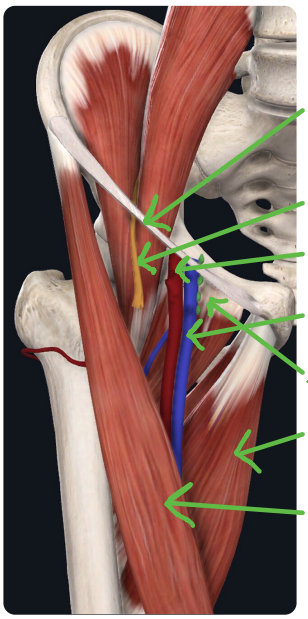

- Superior border
  - Inguinal ligament
- Femoral Nerve
- Femoral Artery
- Femoral Vein
- Lymph Nodes
- Medial boarder
  - Adductor longus
- Lateral border
  - Sartorius

Gait

4 stages of Gait

- Heel strike
- Support
- Toe off
- Swing/carry through

Trendelenburg sign

- Normal = hips stay level
- Positive = one side drops
  - Due to superior Gluteal nerve damage or gluteus minimus/ medius damage/weakness

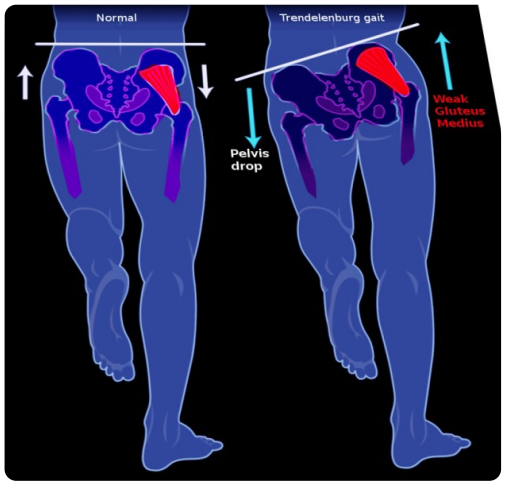

Valgus and Varus deformities

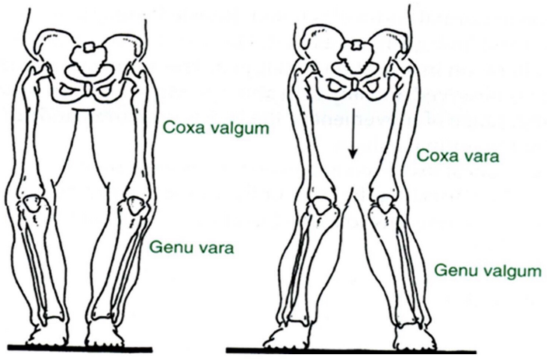

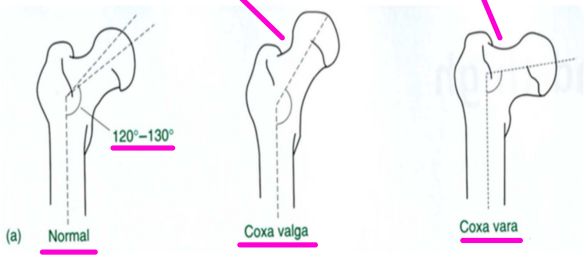

- Valgus = distal bone points Laterally
  - Away from midline
- Varus = distal bone points medially
  - Towards midline
- Coxa valga = knees out
- Gena vara = feet in
- Coxa vara = knocked knees
- Gena valga = feet out